

TREATMENT OF A FEMUR PERIPROTHETIC FRACTURE WITH A DALL-MILES PLATE

Postoperative Care & Complications



N.LASANIANOS, G.MOUZOPOULOS, E.MORAKIS, C.GARNAVOS

1st Orthopaedic Department - General Hospital "Evangelismos"
Athens , Greece

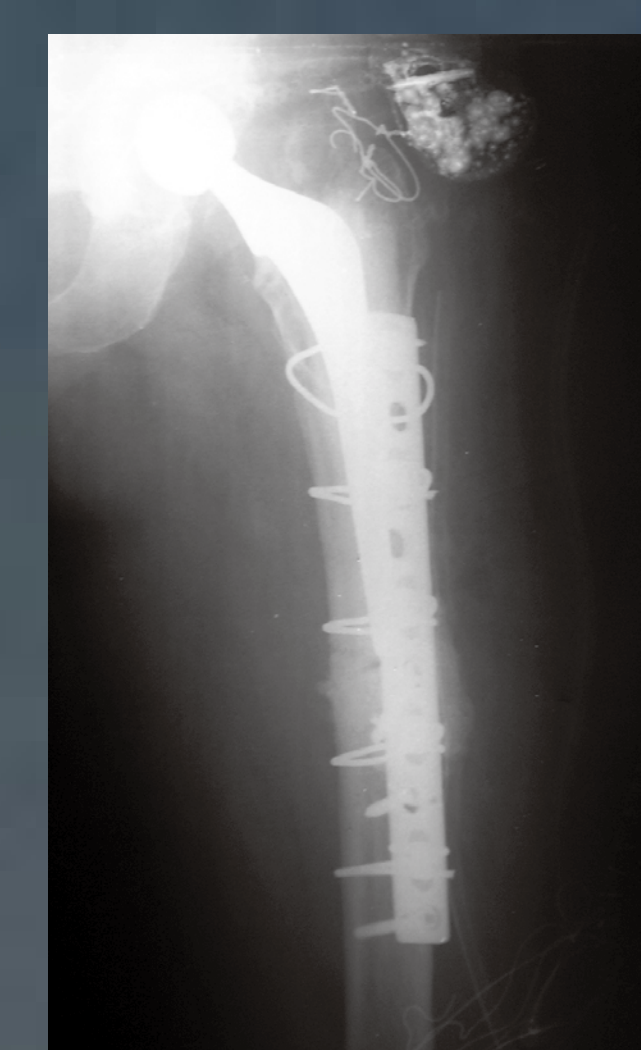
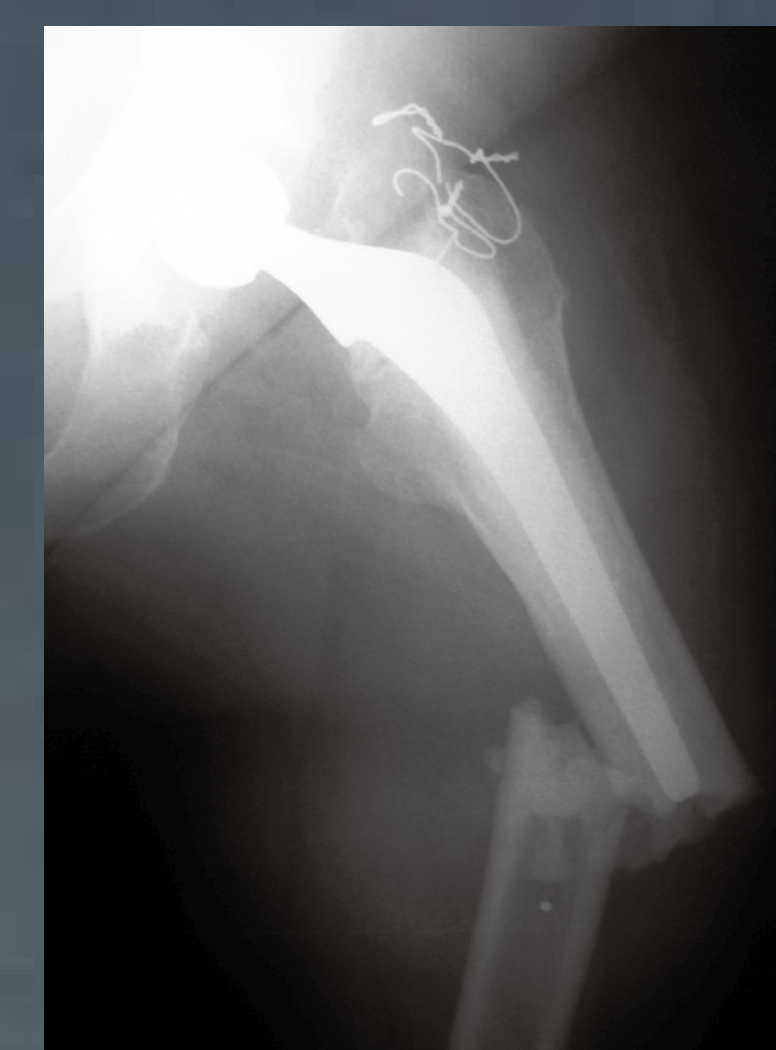
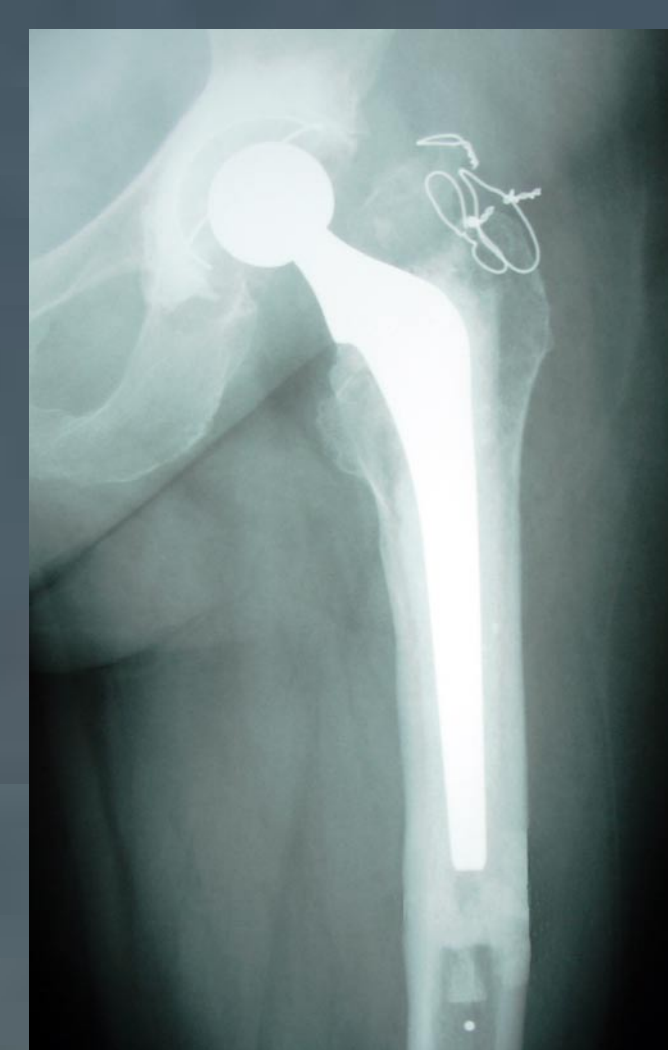
BACKGROUND - AIM : Cerclage fixation, plate fixation, cortical strut grafts & intramedullary nailing are the most usual ways of treatment of periprosthetic fractures. We present the use of the Dall-Miles plate in a femur periprosthetic fracture along with its complications & postoperative results.

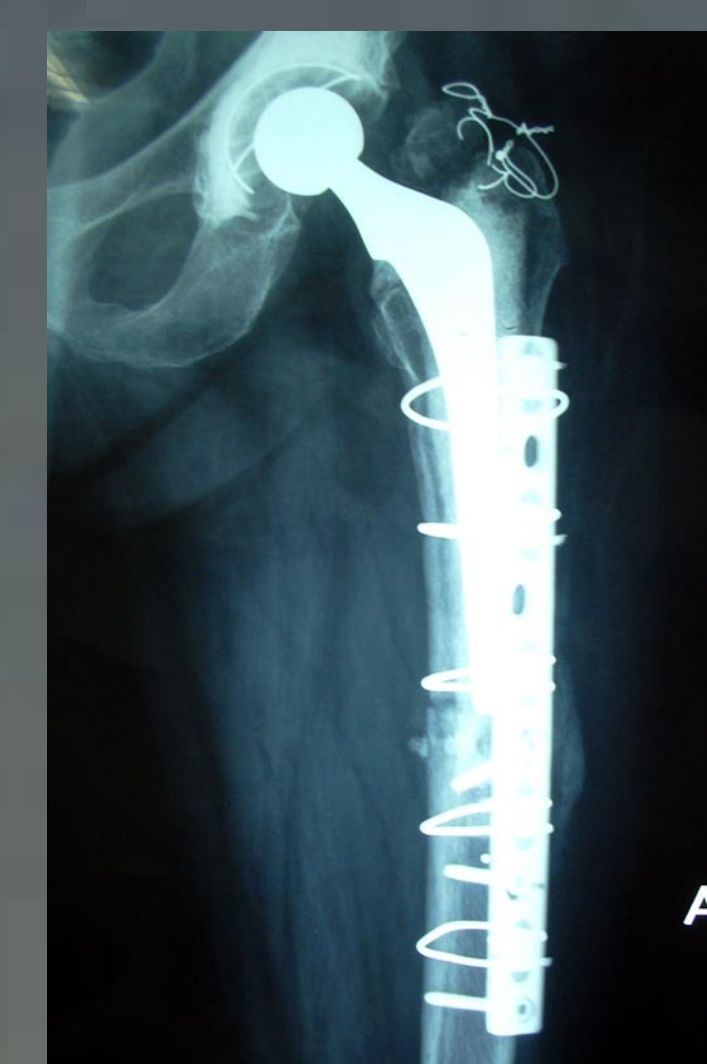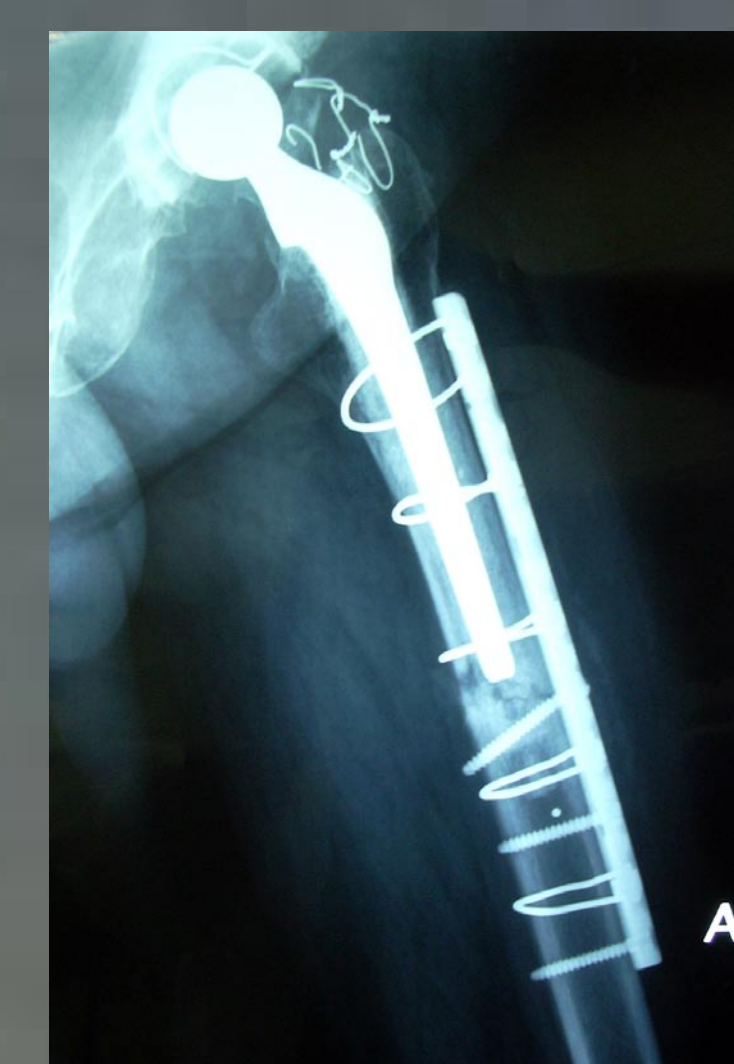MATERIAL - METHOD :

A 68 years old lady who had undergone THA 3 years ago presented to the Emergency Room after a fall. The X-ray control revealed a transverse periprosthetic fracture concerning the femoral diaphysis. The level of the fracture was exactly at the distal point of the femoral component of the THA. (photos 1,2)

The patient underwent surgery during which a Dall-Miles plate was implanted. Cerclage wires were used at the top half of the plate (through the plate) in order to avoid damaging the femoral component of the THA. At the bottom half of the plate apart from cerclage wires, cortical screws were used as well. The fracture was reduced and stabilized without any damage at any of the components of the THA. (photos 3,4,5)



photos 1,2,3

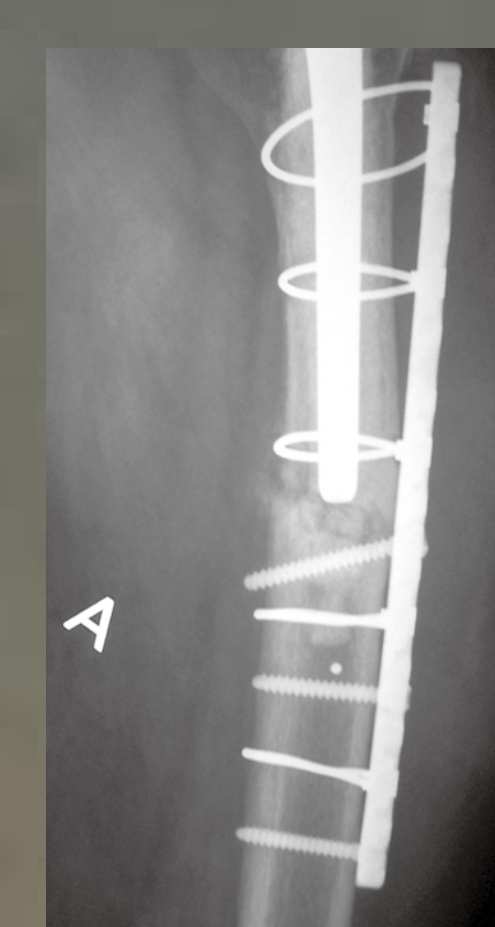
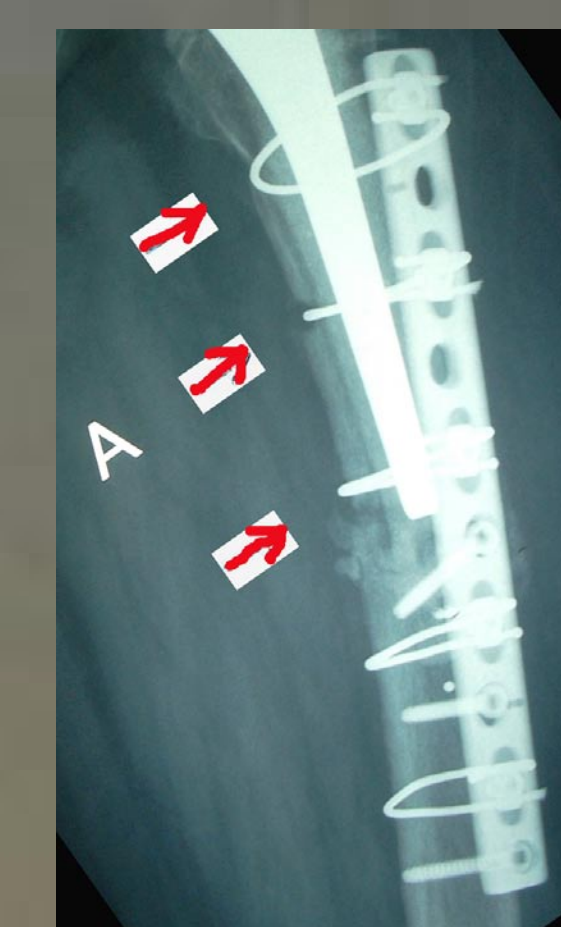


photos 4,5

RESULTS :

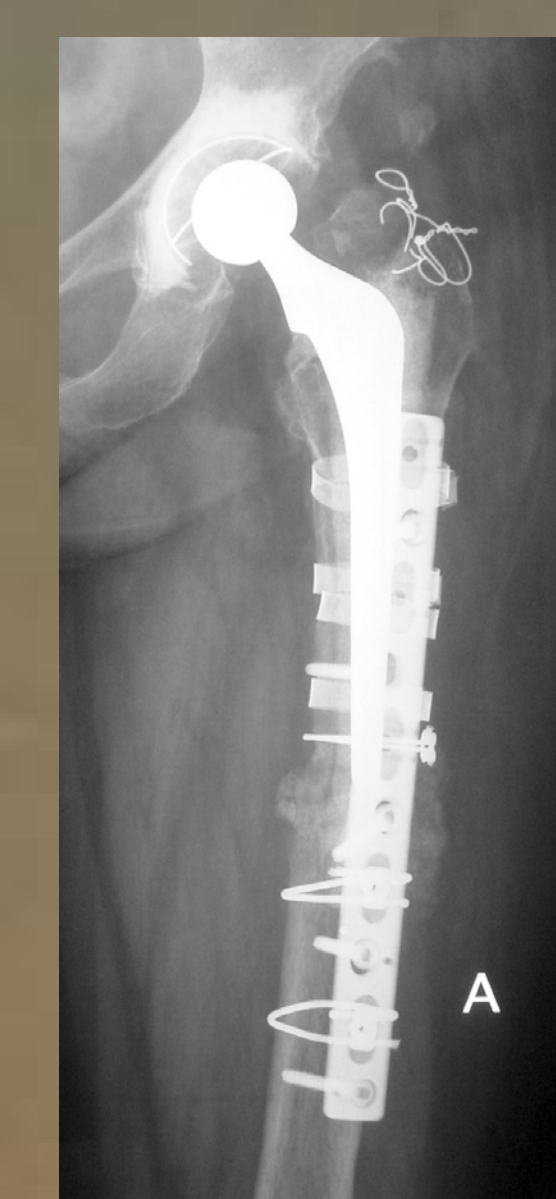
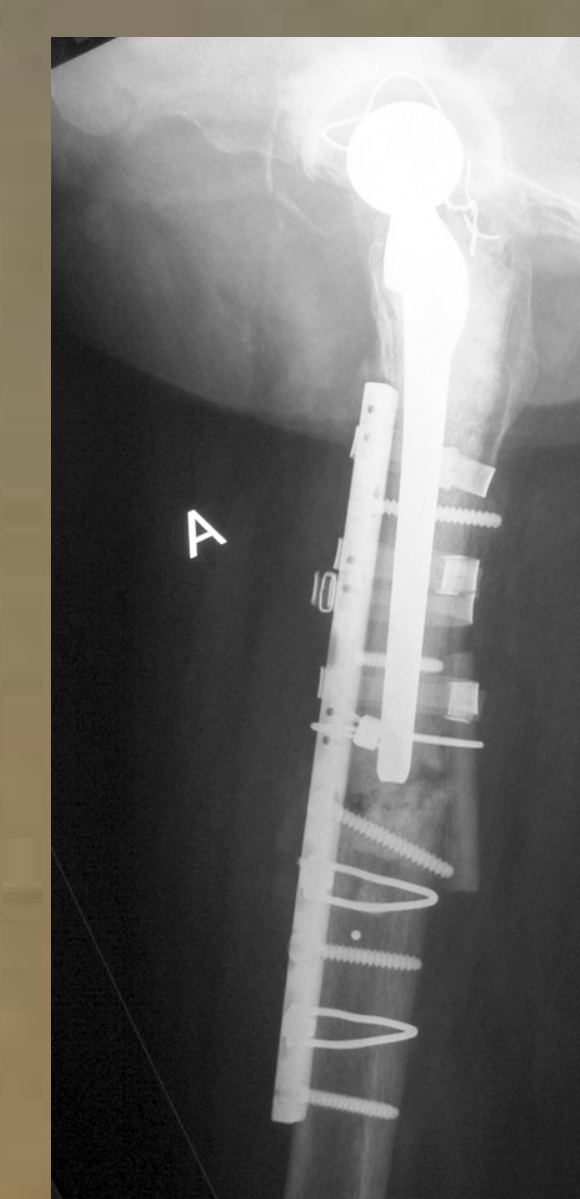
The patient underwent a proper rehabilitation program. At the two months follow up a slight migration of the proximal part of the plate was observed. However the radiological finding was not accompanied with functional disability.

At the six months follow up the patient could perform full weight bearing without any discomfort. Nevertheless the radiological control revealed further lateral migration of the proximal part of the plate. The medial cortex had been injured by the cerclage wires at three points. (photos 6,7)



photos 6,7

A new operation was scheduled during which the wires were replaced by straps. Strut graft was used as well. The THA components and the formed callus remained unaffected. (photos 8,9)
Fifteen months after the last operation the patient faces no problem and the material of the osteosynthesis as well as the callus are being checked radiologically to be in excellent position & shape.



photos 8,9

DISCUSSION :

The B1 & C (according to Vancouver classification) femur periprosthetic fractures are the usual indications for the use of Dall-Miles plates, taking into account that the femoral stem is intact and stable without signs of loosening. Similar internal fixation systems for periprosthetic fractures are the LISS , DCP, Mennen, Ogden plates as well as the Partridge nylon plates and straps.

The type A periprosthetic fractures can be treated conservatively or by simple cerclage wiring. In type B2 & B3 fractures a revision of the femoral stem by a longer one is necessary because of the loosening of the stem in this type of fractures. Additional extramedullary stabilization may be also performed.

Besides the needed stability of the femoral component, the lack of varus deformity is also necessary for the successful use of the Dall-Miles system.

A basic principle in the use of any plate-screw device for femur periprosthetic fractures, is that the distal end of the plate must exceed the distal end of the femoral stem by a distance equal to 2-3 times the diameter of the femur at the level of the tip of the stem.

CONCLUSION :

The Dall-Miles plates consist a very good alternative in the surgical treatment of B1 and C type of femur periprosthetic fractures. The postoperative care and follow up shall be meticulous for the avoidance of cut-out complications. Even if this is the case, the primary fixation of the plate at the right position and the right level allows the surgical correction with minimal invasive procedures.

References :

- 1.Dall-Miles cable & plate fixation system in the treatment of periprosthetic femoral fractures: a review of 20 cases. R.Sandhu, K.Avramidis, C. Johnson. James Paget Hospital, Great Yarmouth, Norfolk, UK.
2. Learmonth ID. The management of periprosthetic fractures around the femoral stem. J Bone Joint Surg Br 2004;86:13-9.
3. Lewallen DG, Berry DK. Femoral fractures associated with hip arthroplasty. In: Morrey BF, editor. Reconstructive surgery of the joints. New York: Churchill-Livingstone; 1996:1273-88.
4. Tsiridis E, Haddad FS, Gie GA. Dall-Miles plates for periprosthetic femoral fractures: a critical review of 16 cases. Injury 2003;34:107-10.
5. Tadross TS, Nanu AM, Buchanan MJ, Checketts RG. Dall-Miles plating for periprosthetic B1 fractures of the femur. J Arthroplasty 2000;15:47-51.
6. Schmötzer H, Tchejeyan GH, Dall DM. Surgical management of intra- and postoperative fractures of the femur about the tip of the stem in total hip arthroplasty. J Arthroplasty 1996;11:709-17.